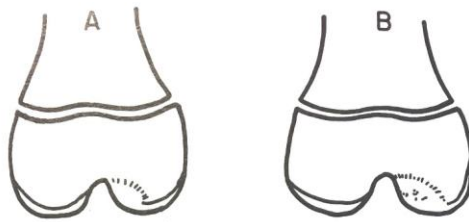


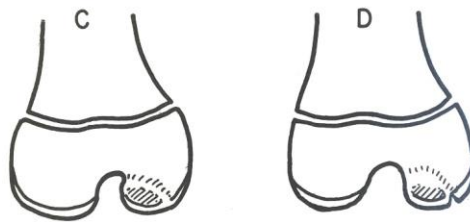
Ostéochondrite disséquante du fémur distal

Classification radiographique

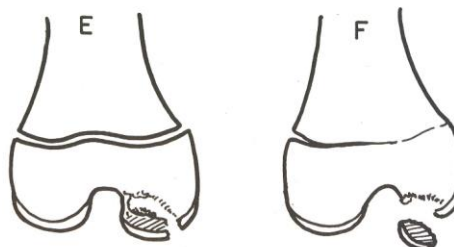
Bedouelle J. Conférences d'Enseignement de la SoFCOT 1988



Stade Ia-Ib



Stade IIa-IIb



Stade III-IV